



UNILATERAL VARIATION OF RENAL ARTERY AND RENAL PELVIS A CASE STUDY

Dr Jithesh C*

Associate Professor, Ashtangam Ayurveda Chikitsalayam and Vidyapeedham
*Corresponding Author

Dr Jisha R John

Associate Professor, Nangelil Ayurveda Medical College

Dr Varun Vinayak

Assistant Professor, Ashtangam Ayurveda Chikitsalayam and Vidyapeedham

ABSTRACT

Knowledge of the anatomical relations are essential for the surgeons to avoid injury during different surgical procedures that requires an approach to the renal arteries. During our dissection of a male cadaver aged about 60-years, we observed unilateral variation in renal artery and renal pelvis. On the left side renal arteries (main and accessory renal arteries) were altered and a bifurcated renal pelvis was seen. Radiologists and surgeons must be aware of all possible variations to avoid diagnostic pitfalls and for optimization of surgical techniques to prevent postsurgical morbidities.

KEYWORDS : Renal artery, Renal pelvis, calyx, infundibulum

INTRODUCTION

The renal arteries are two of the largest branches of abdominal aorta and arise laterally from it, just below the origin of Superior mesenteric artery. The Right is longer and usually arises slightly higher than the left. It passes posterior to Inferior vena cava, right renal vein, head of pancreas and second part of duodenum. The left renal artery arises a little lower down and passes behind the left renal vein, body of pancreas and splenic vein [1] The paired renal arteries take 20% of cardiac output to supply organs that represent less than one hundredth of total body weight. They supply kidneys through number of divisions as segmental, lobar, interlobar and arcuate arteries, which are end arteries with no anastomoses. Arcuate arteries divide into interlobular arteries, which give rise to afferent arteries to the glomeruli.

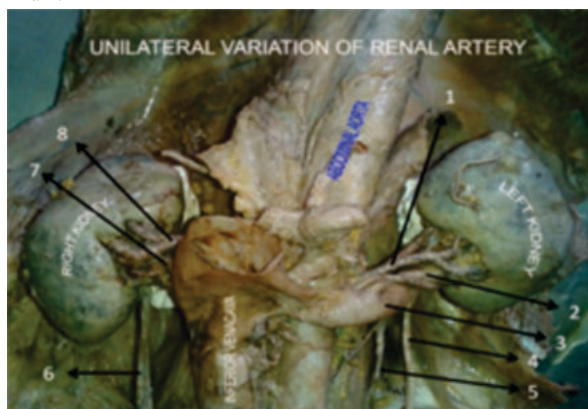Renal pelvis, normally formed from the junction of two infundibular, one from the upper and one from the lower pole calyces, but there may be a third, draining the calyces in the midportion of kidney. The funnel shaped renal pelvis tapers as it passes infero-medially, traversing the renal hilum to become continuous with the ureter.[2]

CASE REPORT

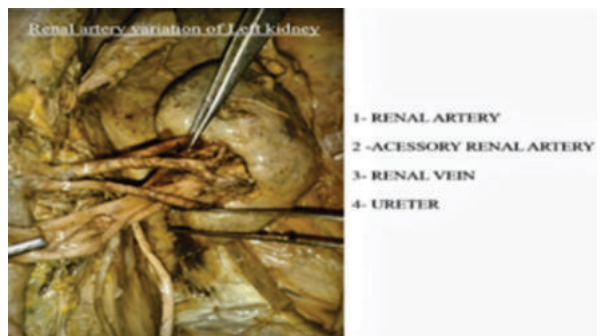
We found unilateral variation of renal artery and renal pelvis on the left side during the routine dissection of about 60 years old male cadaver, in Alva's Ayurvedic Medical College, Moodbidri.

Variation In The Renal Artery

There are two renal arteries, main and accessory before entering the hilum.

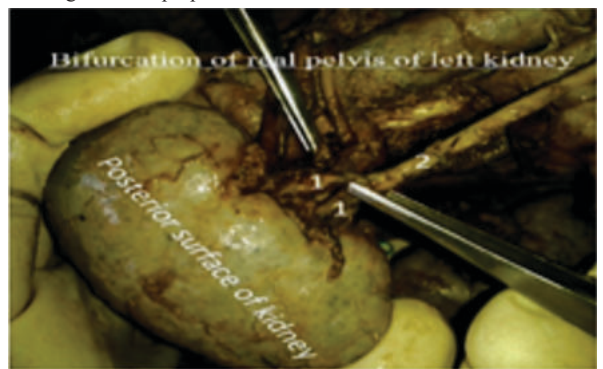

1. left renal artery
2. Accessory renal artery
3. left renal vein
4. left ureter
5. Testicular vein
6. Right ureter
7. Right renal vein
8. Right renal artery



Variation In Renal Pelvis

Bifurcated renal pelvis on the left kidney after leaving hilum, before forming the ureter proper.



- 1 – Unilateral bifid renal pelvis.
- 2 – Ureter

DISCUSSION

A single renal artery to each kidney is present in 70% of individuals. Near the renal hilum, each artery divides into an anterior and posterior division and these divide into segmental arteries that supply renal vascular segments.

Accessory renal arteries are common in 30% and usually arise from the aorta above or below the main renal artery and follows to the renal hilum, which are regarded as persistent embryonic lateral splanchnic arteries. Rarely accessory renal arteries arise from the coeliac or superior mesenteric arteries near the aortic bifurcation or from common iliac arteries.[2]

There may be considerable variation in the arrangement of the infundibula and in the extent to which the pelvis is intrarenal or extrarenal. Rarely the entire renal pelvis has been found to lie inside the sinus of kidney with pelvi-ureteric region occurs either in the vicinity of renal hilum or completely within renal sinus.[2]

The variations in the renal vessels are mainly due to various developmental positions of the kidney.[3]

Renal arteries exhibit a high degree of variations compared to the renal veins. A variation occurring in both arteries and veins together is rare; also, variations among the renal veins are not as common as arteries [4] Ureter starts developing from the ureteric bud in 5th week of intrauterine life as a diverticulum from dorsomedial side of mesonephric duct. It grows upwards towards metanephric tissue. The ureteric bud bifurcates when it comes in contact with the metanephric blastema induced by glial cell line derived neurotrophic factor. Subsequent divisions of the ureteric bud and the mesenchyme forms the gross structure of kidney with major and minor calyces.

Lack of Glial cell line derived neurotrophic factor or premature splitting of ureteric bud before it reaches to the nephrogenic cells gives rise to incomplete or branched ureter.

CONCLUSION

The origin, number and topography of accessory renal arteries are complex are associated with renal embryogenesis. Renal vasculature variations are important for the angiographers and urologists.[5]. Knowledge of the variations of the renal arteries has grown in importance with the increasing number of renal transplants, vascular reconstructions and various surgical, urological and radiological techniques. The knowledge of entry of renal veins into the inferior vena cava and their variations is equally important during catheterization and planning Porto-renal shunt procedures.[6]

REFERENCES

1. Standring, Susan., et al. Gray's Anatomy: The Anatomical Basis of Clinical Practice, 39th edition, Elsevier Churchill Livingstone, 2005; 1118
2. Standring, Susan., et al. Gray's Anatomy: The Anatomical Basis of Clinical Practice, 39th edition, Elsevier Churchill Livingstone, 2005; 1273, 1274
3. Moore KL, Persaud TVN. The Developing Human: Clinically Oriented Embryology. 8th Ed., Philadelphia, Saunders, Elsevier. 2008; 249–251.
4. Soni S, Wadhwa A. Multiple variations in the paired arteries of abdominal aorta clinical implications. Journal of Clinical and Diagnostic Research. 2010; 4: 2622–2625.
5. Krishnaswamy N Rao KGM, Somayaji SN, Koshy S, Rodrigues V. An unusual case of unilateral additional right renal artery and vein. Int J Anat Var [IJAV] 2010; 3: 9-11
6. Satyapal KS. Classification of the drainage patterns of the renal veins. J Anat. 1995; 186: 329–333